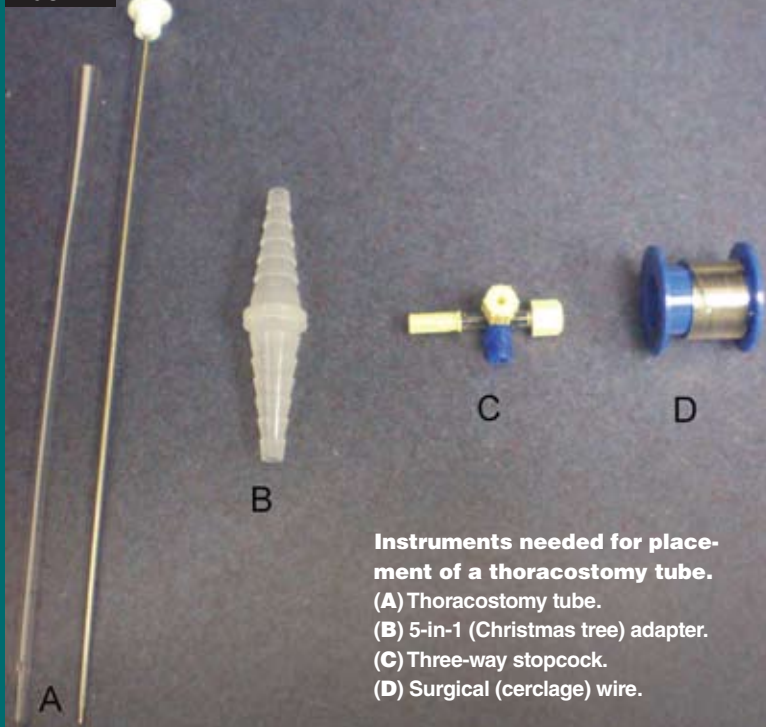


Basic Steps of Thoracostomy Tube Placement

▶ The tubes should be flexible but firm and resistant to collapse.⁴⁷ Polyvinyl thoracic drainage tubes with stylets to assist with placement are commercially available (Argyle, Sherwood Medical) (FIGURE A). Red rubber feeding tubes may cause tissue reaction but may be used if other commercial tubes are unavailable and long-term placement is not anticipated.²

FIGURE A



- ▶ The appropriate size of the tube is determined by the size of the mainstem bronchus on radiographs.^{45,47} Commercial tubes come with preplaced holes; however, additional holes can be added to achieve a total of three to five holes, which is sufficient for drainage. Many commercial tubes also have an incorporated longitudinal radiopaque marker to allow visualization of the tube on radiographs. If additional holes are placed, the last hole should be on the radiopaque marker line to allow assessment of the tube's placement within the thoracic cavity.
- ▶ The tube is generally placed with the animal under general anesthesia. If the animal's status precludes general anesthesia, local intercostal nerve blocks that include the parietal pleura may be used.^{45,47}
- ▶ The lateral thorax is clipped and prepared aseptically before tube placement.

For medium and large dogs:

1. Make a small stab incision in the skin in the dorsal one-third of the thorax at the 10th to 12th intercostal spaces.
2. Make a tunnel in the subcutaneous tissue three to four intercostal spaces cranially using the tube with the stylet. If using a red rubber catheter or a tube without a stylet, use a pair of large hemostatic forceps to create the tunnel and advance the tube.⁴⁸
3. Rotate the tube perpendicular to the thoracic wall.

4. With one quick, brisk thrust, pass the tube (or hemostat) through the intercostal musculature into the thoracic cavity. However, use caution, as too brisk an entry into the thoracic cavity may cause inadvertent damage to thoracic organs. Also, as for thoracocentesis, be careful to avoid the large intercostal vessels and nerves just caudal to the ribs.
5. Once penetration is achieved, lay the tube parallel to the spine, advance it slightly, and remove the stylet, passing the tube cranially and ventrally into the cranial pleural space.
6. Obtain a radiograph to ensure proper placement of the tube in the cranioventral pleural space to approximately the level of the second rib⁴⁸ (FIGURE B).
7. Place a purse-string suture at the entry site into the thoracic cavity to prevent leakage of air or fluid into the subcutaneous tissue.⁴⁸
8. Suture the tube to the skin using a Chinese finger-trap suture pattern or variation thereof.⁴⁸
9. Attach the tubing to a three-way stopcock, either directly or with a five-in-one (Christmas tree) adapter.
10. Secure the tubing to the stopcock with surgical wire to allow intermittent drainage.
11. Cover the tube entry with a few gauze sponges impregnated with a small amount of iodine ointment, followed by a soft, padded bandage or tubular stockinet over the chest to protect the tube.
12. Apply an Elizabethan collar to prevent premature pulling by the animal.

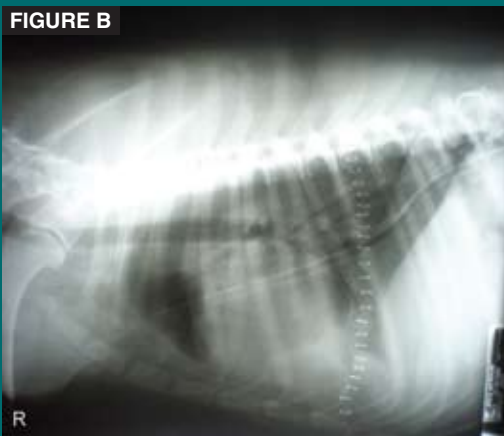


FIGURE B
Radiograph showing proper placement of a thoracostomy tube.

For small dogs, puppies, and cats, in which the chest is too compressible for any technique that requires force, or to avoid having to thrust the tube into the thorax in larger dogs, use the following technique:

1. After proper preparation of the area, pull the skin forward to the appropriate space.⁴⁸
2. Make the skin incision, followed by dissection down through the chest wall.⁴⁸
3. Insert the tube in an open fashion or use it to gently penetrate the inner intercostal layer.⁴⁸
4. Allow the skin to retract to its normal position, resulting in subcutaneous tunneling of the tube.⁴⁸
5. Follow steps 6 through 12 above.